Original Article

DOI: 10.7860/NJLM/2026/89474.3017

Pathology Section

Histopathological Spectrum of Lesions in Resected Specimens of the Lower Gastrointestinal Tract at a Tertiary Healthcare Centre in Northern Odisha: A Cross-sectional Study

KALYANI PRAVA GOUDA[1], RASHMI REKHA MAHAPATRA[2], TAPAN KUMAR BEHERA[3]

BY-NC-ND

ABSTRACT

Introduction: The lower Gastrointestinal (GI) tract is a common site for a wide spectrum of lesions ranging from non-neoplastic inflammatory conditions to malignant neoplasms. Histopathological evaluation remains the gold standard for diagnosis, guiding management and prognosis. As the histopathological spectrum and distribution of these lesions may vary across different geographic and healthcare settings, the present study was undertaken to evaluate the spectrum of lesions encountered in resected lower GI tract specimens in a tertiary healthcare centre in Northern Odisha.

Aim: To evaluate the histopathological spectrum of lesions in resected specimens of the lower GI tract, and to analyse their demographic distribution, frequency, and anatomical location.

Materials and Methods: The present observational, cross-sectional study was conducted in the Departments of Pathology and Surgery in a tertiary healthcare centre, PRM Medical College and Hospital, Baripada, Odisha, India from January 2021 to January 2024. A total of 196 resected specimens of the lower GI tract, including appendectomy, bowel resection, hemicolectomy, and colectomy specimens, from patients of all age groups and both sexes were included. Endoscopic and biopsy specimens, inadequate specimens, and autolysed specimens were excluded from the study. Gross and microscopic findings were analysed, and tumours were classified according to the World Health Organisation (WHO) Classification of Tumours of the Digestive System, 5th edition (2019).

Results: Out of 196 cases, 183 (93.37%) were non-neoplastic and 13 (6.63%) were neoplastic. The most common age group was 21-30 years 50 (25.5%), with male predominance (M=1.5:1). Appendiceal lesions accounted for the majority of non-neoplastic cases 161/183 (87.97%), while intestinal tuberculosis was the next most common diagnosis 8/183 (4.37%). Among neoplastic lesions, adenocarcinoma was the most frequent 9/13 (69.23%), followed by tubular adenoma 2/13 (15.38%). The appendix was the most commonly involved site 163 (83.16%), followed by the ileum 17 (8.7%). Abdominal pain 118 (60.2%) was the leading clinical presentation, followed by vomiting 71 (36.2%) and fever 38 (19.39%).

Conclusion: Non-neoplastic lesions, particularly appendiceal lesions, formed the bulk of lower GI tract resections, while adenocarcinomas predominated among neoplastic lesions. The findings highlight the broad histopathological spectrum encountered in resected lower GI tract specimens and emphasise the importance of histopathological examination for accurate diagnosis and detection of clinically significant neoplastic lesions.

Keywords: Adenocarcinoma, Bowel resection, Hemicolectomy, Non-neoplastic lesions, Neoplastic lesions

INTRODUCTION

The lower GI tract encompasses the jejunum and ileum of the small intestine and the large intestine, including the caecum, appendix, colon, rectum, and anal canal. It is affected by a wide spectrum of pathological conditions ranging from inflammatory and infectious disorders to benign and malignant neoplasms [1,2]. Diseases of the small intestine include developmental anomalies, malabsorption syndromes, inflammatory and infectious disorders, intestinal obstruction, benign tumours and tumour-like lesions, as well as malignant neoplasms such as carcinoma and lymphoma [3]. Similarly, the large intestine and anal canal may be affected by a diverse range of inflammatory, infectious, developmental, benign, and malignant lesions [4].

Histopathological examination of resected specimens remains essential for establishing a definitive diagnosis of lower GI lesions. It enables distinction between non-neoplastic and neoplastic conditions and provides accurate characterisation and classification of lesions, including assessment of prognostically relevant pathological features. In neoplastic lesions, histopathological evaluation is particularly important for determining tumour type, grade, extent of invasion, and other parameters that influence management and prognosis [5].

The frequency and distribution of lower GI lesions vary among different populations and healthcare settings, reflecting differences in demographic characteristics, disease prevalence, environmental factors, and referral patterns. The spectrum encountered in resected specimens may also differ from that observed in biopsy-based studies because surgical specimens predominantly represent lesions requiring operative management. Consequently, institutional studies are valuable in defining the local pattern of lower GI diseases.

Although several studies have reported the histopathological spectrum of GI lesions, the relative distribution of non-neoplastic and neoplastic lesions varies considerably across different geographical and institutional settings. Recent data specifically addressing the spectrum of lesions in resected lower GI specimens in the present setting are limited. Establishing this local pattern may provide useful baseline data for clinicians, surgeons, and pathologists and facilitate comparison with findings from other populations.

Therefore, the present study was undertaken to evaluate the histopathological spectrum of lesions encountered in resected specimens of the lower GI tract, with emphasis on their distribution according to anatomical site and pathological category.

MATERIALS AND METHODS

The present observational, cross-sectional study was conducted in the Departments of Pathology and Surgery at PRM Medical College and Hospital, Baripada, Odisha, from January 2021 to January 2024. The study was undertaken after obtaining approval from the Institutional Ethics Committee (IEC) prior to its commencement (IEC reference no. 46/7th IEC Meeting).

For the purpose of this study, the term "lower gastrointestinal tract" was used in accordance with the National Library of Medicine (NLM) Medical Subject Headings (MeSH), which includes the small intestine distal to the duodenum and the large intestine [2]. Accordingly, jejunal, ileal, and large-intestinal specimens extending to the anal canal were included.

Inclusion criteria: All consecutive resected specimens of the lower GI tract, from jejunum to anal canal, received in the study Institute were included. These comprised appendectomy specimens, small and large bowel resections, hemicolectomy, sigmoid and rectal resections, abdominoperineal resections, and other lower GI surgical specimens. Patients of all ages and both genders were included.

Exclusion criteria: Excisional, incisional, endoscopic, and other biopsy specimens, as well as inadequate and autolysed samples, were excluded.

Consecutive sampling was used, and all eligible specimens received during the study period were included. A total of 196 cases constituted the final sample size.

Study Procedure

All specimens were fixed in 10% neutral buffered formalin, routinely processed, paraffin-embedded, sectioned, and stained with Haematoxylin and Eosin (H&E). Relevant demographic and clinical details, including age, sex, presenting symptoms and their duration, clinical/provisional diagnosis, anatomical site, type of surgical specimen, and relevant investigations, were obtained from histopathology requisition forms and departmental records. Gross and microscopic findings were recorded for each specimen.

The histopathological parameters assessed included anatomical site, type of lesion, inflammatory and other associated changes, and, in neoplastic lesions, tumour type, differentiation/grade, depth of invasion, lymphovascular and perineural invasion, lymph-node status, and resection margin status, wherever applicable. All slides were independently examined by two pathologists, and any discrepancy was resolved by consensus.

Lesions were categorised into non-neoplastic and neoplastic lesions. Neoplastic lesions were classified according to the WHO Classification of Tumours: Digestive System, 5th edition (2019), while non-neoplastic lesions were diagnosed based on established histopathological criteria and clinicopathological correlation [6].

STATISTICAL ANALYSIS

Data were entered and analysed using Microsoft Excel 2019. Descriptive statistics were used, and categorical variables were expressed as frequencies and percentages. The distribution of lesions was analysed with respect to age, sex, clinical presentation, and anatomical site. Findings were tabulated and presented using appropriate charts and tables for better interpretation.

RESULTS

Out of 196 cases studied, non-neoplastic lesions predominated, accounting for 183 cases (93.37%), while neoplastic lesions were observed in 13 cases (6.63%) [Table/Fig-1]. The highest frequency of lower GI tract lesions was noted in the 21-30-year age group, followed by the 11-20-year age group, with an overall male predominance [Table/Fig-2].

Lesions	n (%)
Non-neoplastic	183 (93.37%)
Neoplastic	13 (6.63%)

[Table/Fig-1]: Distribution of lower GI tract lesions according to type.

Age (year)	Male	Female	n (%)
1 month-10	4	4	8 (4.08)
11-20	30	18	48 (24.49)
21-30	33	17	50 (25.51)
31-40	21	16	37 (18.88)
41-50	15	13	28 (14.29)
51-60	9	5	14 (7.14)
61-70	6	1	7 (3.57)
71-80	1	2	3 (1.53)
81-90	0	0	0
91-100	0	1	1 (0.51)
Total	119	77	196 (100)

[Table/Fig-2]: Distribution of lower GI lesions according to the age and gender.

Among the 183 non-neoplastic lesions, appendiceal involvement was the most frequent, accounting for 161 (87.97%) cases, followed by tubercular lesions of the intestine in 8 (4.37%) cases. Appendiceal lesions collectively accounted for 161 (87.97%) cases, comprising acute, suppurative, acute-on-chronic, recurrent/chronic, perforated, and tuberculous lesion of the appendix [Table/Fig-3]. The histopathological features of intestinal tuberculosis are shown in [Table/Fig-4]. Other non-neoplastic lesions observed included eosinophilic colitis [Table/Fig-5], Meckel's diverticulum [Table/Fig-6], intestinal gangrene [Table/Fig-7], and Hirschsprung disease [Table/Fig-8], among others.

Type	n (%)
Acute appendicitis	84 (45.90)
Acute suppurative appendicitis	8 (4.37)
Acute on chronic appendicitis	3 (1.64)
Recurrent/chronic appendicitis	64 (34.97)
Acute appendicitis with perforation	1 (0.55)
Tuberculosis of appendix	1 (0.55)
Nonspecific inflammation	6 (3.28)
Gangrene	2 (1.09)
Eosinophilic colitis	1 (0.55)
Necrotising enterocolitis	1 (0.55)
Intestinal tuberculosis	8 (4.37)
Meckel's diverticulum	3 (1.64)
Hirschsprung disease	1 (0.55)
Total	183 (100)

[Table/Fig-3]: Frequency distribution of non-neoplastic lesions based on histopathological diagnosis in resected specimens of the lower GI tract.

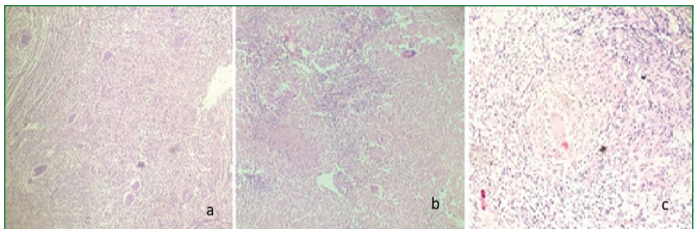

[Table/Fig-4]: Photomicrographs of intestinal tuberculosis showing epithelioid cell granulomas with Langhans giant cells without demonstrable caseation necrosis: a,b) H&E stain, scanner view; c) H&E stain, ×200.

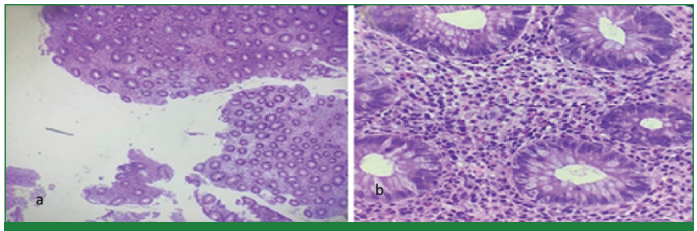

[Table/Fig-5]: Photomicrographs of eosinophilic colitis showing increased eosinophilic infiltration within the colonic mucosa: a) H&E stain, scanner view; b) H&E stain, ×400.

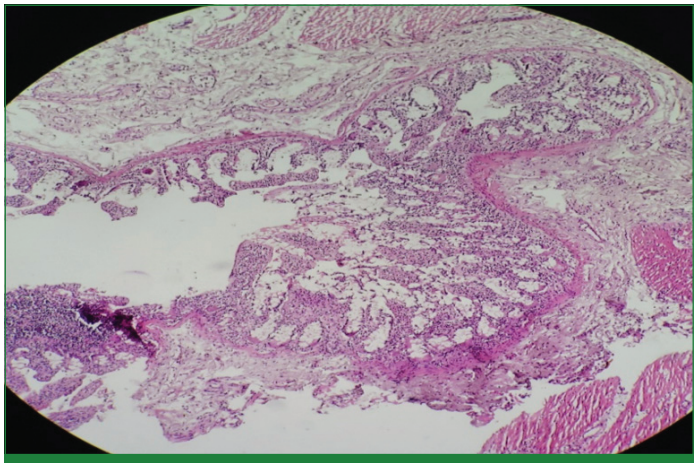

[Table/Fig-6]: Photomicrograph of Meckel's Diverticulum showing an outpouching with all four layers of the intestinal wall H&E stain, ×100.

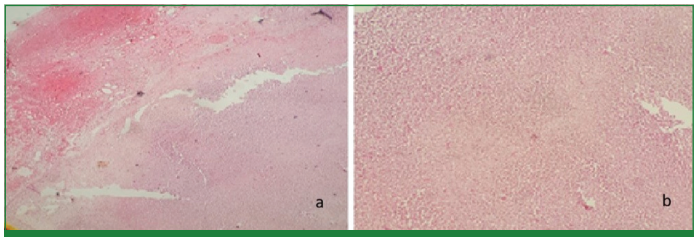

[Table/Fig-7]: Photomicrographs of intestinal gangrene showing transmural necrosis of the intestinal wall: a) H&E stain, ×100; b) H&E stain, ×200.

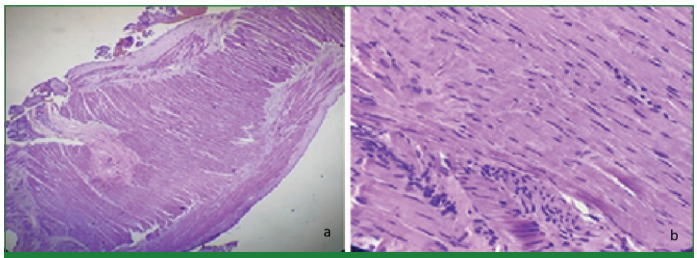

[Table/Fig-8]: Photomicrographs of Hirschsprung disease showing absence of ganglion cells in the affected segment: a) H&E stain, scanner view; b) H&E stain, ×100.

Of the 13 neoplastic cases, adenocarcinoma was the most common lesion, observed in 9 (69.23%) cases [Table/Fig-9]. Among the adenocarcinomas, moderately differentiated adenocarcinoma was the most frequent (4 cases) [Table/Fig-10], followed by well differentiated adenocarcinoma (3 cases) [Table/Fig-11] and poorly differentiated adenocarcinoma (2 cases) [Table/Fig-12]. The poorly differentiated adenocarcinomas comprised one signet-ring cell carcinoma of the ileum and one mucinous adenocarcinoma of the rectum. Other neoplastic lesions included tubular adenoma 2 (15.38%) [Table/Fig-13], neuroendocrine tumour of the appendix 1 (7.69%), and jejunal lipoma 1 (7.69%) case [Table/Fig-14]. Lymphovascular invasion was identified in five cases, while lymph node metastasis was identified in one case. The detailed histopathological features, depth of invasion, resection margin status, lymph node status, and pathological TNM stage of the carcinomas are presented in [Table/Fig-15].

The appendix was the most frequently represented site, comprising 163 (83.16%) of the 196 specimens, followed by the ileum with 17 (8.67%) specimens [Table/Fig-16]. Clinically, abdominal pain was the most common presenting symptom, observed in 118 (60.2%) cases, followed by vomiting in 71 (36.22%) cases, fever in 38 (19.39%) cases, and loss of appetite in 20 (10.2%) cases. [Table/Fig-17].

Type	n (%)	
Tubular adenoma, colon	2	15.38
Signet-ring cell carcinoma, ileum (poorly differentiated)	1	7.69
Adenocarcinoma, colon (moderately differentiated)	3	23.08
Mucinous adenocarcinoma, rectum (poorly differentiated)	1	7.69
Adenocarcinoma, rectosigmoid (well differentiated)	2	15.38
Mucinous adenocarcinoma, caecum (moderately differentiated)	1	7.69
Adenocarcinoma appendix (well differentiated)	1	7.69
Neuroendocrine tumour of appendix (well differentiated, grade 1)	1	7.69
Lipoma, jejunum	1	7.69
Total	13	100

[Table/Fig-9]: Frequency distribution of neoplastic lesions of the lower GI tract according to histopathological diagnosis.

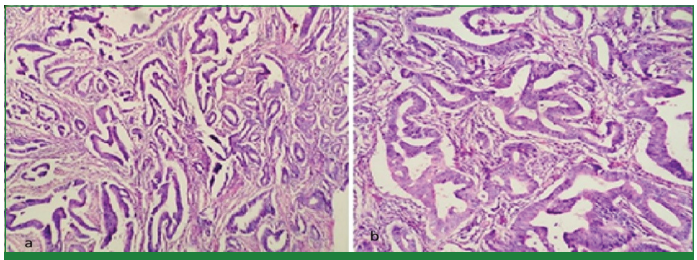

[Table/Fig-10]: Photomicrographs of moderately differentiated adenocarcinoma of the colon showing simple and complex irregular tubules with loss of nuclear polarity: a) H&E stain, ×100; b) H&E stain, ×200.

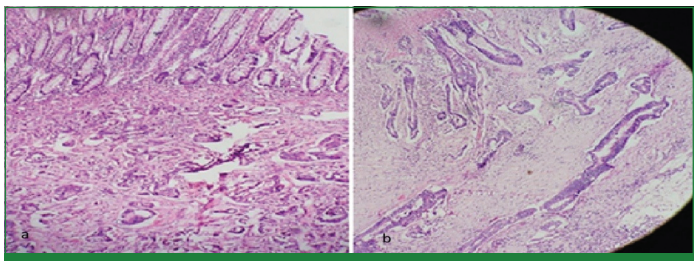

[Table/Fig-11]: Photomicrographs of well-differentiated adenocarcinoma of the rectosigmoid junction showing: a) Neoplastic cells forming glandular structures; and b) Tumour glands invade through muscularis propria into pericolorectal tissue (H&E stain, ×100).

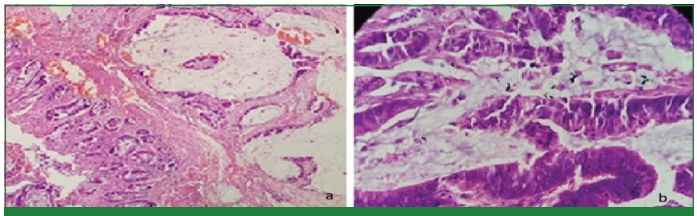

[Table/Fig-12]: Photomicrographs of poorly differentiated mucinous adenocarcinoma of the rectum showing abundant extracellular mucin pools containing malignant glands: a) H&E stain, ×100; b) H&E stain, ×200.

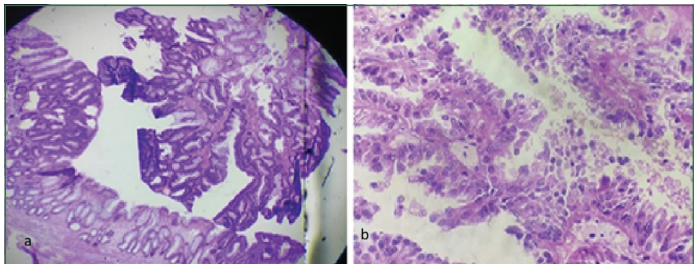

[Table/Fig-13]: Photomicrographs of tubular adenoma showing polypoid colonic mucosa lined by dysplastic epithelium composed of pseudostratified, hyperchromatic, elongated nuclei: a) H&E stain, ×100; b) H&E stain, ×400.

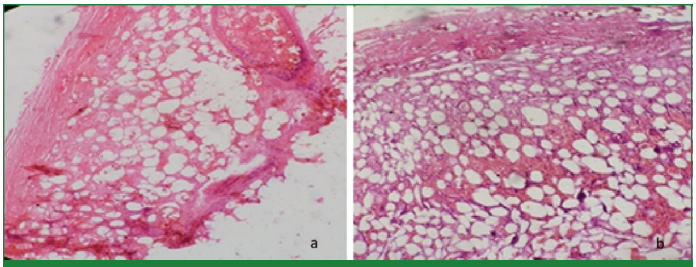

[Table/Fig-14]: Photomicrograph of jejunal lipoma showing sheets of mature adipocytes within the intestinal wall: a,b) H&E stain, ×100.

DISCUSSION

In the present study, non-neoplastic lesions predominated, comprising 183 of 196 (93.37%) cases, while neoplastic lesions accounted for 13 (6.63%) cases. This finding is broadly comparable with the observations of Patel VK et al., Jasani JH et al., and Prajapati P et al., who reported non-neoplastic lesions in 95.34%, 95.0%, and 94.6% of cases, respectively [7-9]. In particular, the findings of Prajapati P et al., based on 500 lower GI specimens, closely resemble those of the present study, with only a marginal difference in the proportion of non-neoplastic lesions (94.6% vs. 93.37%) [9]. However, the proportion observed in the present study was substantially higher than that reported by Roka K et al., (73.33%), Suvernakar SV (58%), and Nanavati MG et al., (78.5%) [10-12], and markedly higher than the equal distribution of non-neoplastic and neoplastic lesions reported by Binayke R et al., (50% each) [13]. These differences may be attributable to variations in study population, specimen selection, anatomical distribution of lesions, and inclusion of biopsy versus resection specimens.

Type of carcinoma	Grade	LVI	Depth of invasion	Margin status	LN status	TNM stage
Signet-ring cell carcinoma, ileum	PD	Identified	Through muscularis propria into subserosa	Negative for invasive carcinoma	Not assigned	$pT3N_{NA}M_{NA}$
Adenocarcinoma, colon	MD	Identified	Through muscularis propria to pericolic tissue	Negative for invasive carcinoma	Negative for tumour	$pT3N0M_{NA}$
Adenocarcinoma, colon	MD	Identified	Through muscularis propria to pericolic tissue	Negative for invasive carcinoma	Involved	$pT3N1M_{NA}$
Adenocarcinoma, colon	MD	Not identified	Invades into muscularis propria	Negative for invasive carcinoma	Not assigned	$pT2N_{NA}M_{NA}$
Mucinous adenocarcinoma, rectum	PD	Identified	Invades into muscularis propria	Positive for invasive carcinoma	Not assigned	$pT2N_{NA}M_{NA}$
Adenocarcinoma, rectosigmoid	WD	Not identified	Invades into muscularis propria	Negative for invasive carcinoma	Not assigned	$pT2N_{NA}M_{NA}$
Adenocarcinoma, rectosigmoid	WD	Not identified	Through muscularis propria to pericolorectal tissue	Proximal margin positive for invasive carcinoma	Not assigned	$pT3N_{NA}M_{NA}$
Mucinous adenocarcinoma, caecum	MD	Identified	Through muscularis propria to pericolic tissue	Negative for invasive carcinoma	Negative for tumour	$pT3N0M_{NA}$
Adenocarcinoma appendix	WD	Not identified	Invades into muscularis propria	Negative for invasive carcinoma	Not assigned	$pT2N_{NA}M_{NA}$

[Table/Fig-15]: Histopathological features and pathological staging of carcinomas.
WD: Well differentiated; MD: Moderately differentiated; PD: Poorly differentiated; LVI: Lymphovascular invasion; LN: Lymph node; pTNM: Pathological tumour-node-metastasis stage; N_{NA}: PN Not assigned; M_{NA}: pM Not applicable

Site	Non-neoplastic	Neoplastic	n (%)
Jejunum	0	1	1 (0.51)
Ileum	16	1	17 (8.67)
Jejunum + Ileum	1	0	1 (0.51)
Ileum + Caecum	3	0	3 (1.53)
Caecum	0	1	1 (0.51)
Colon	1	4	5 (2.55)
Caecum + Colon	1	1	2 (1.02)
Appendix	161	2	163 (83.16)
Rectum	0	1	1 (0.51)
Rectum + Sigmoid colon	0	2	2 (1.02)
Anal canal	0	0	0
Total	183	13	196 (100)

[Table/Fig-16]: Distribution of lower GI tract lesions according to anatomical site and type.

Clinical symptoms	n (%)
Pain abdomen	118 (60.20)
Vomiting	71 (36.22)
Fever	38 (19.39)
Mass per abdomen	3 (1.53)
Loss of appetite	20 (10.20)
Weight loss	16 (8.16)
Diarrhoea	6 (3.06)
Constipation	7 (3.57)
Anaemia	7 (3.57)
Blood in stool	7 (3.57)
Abdominal distension	1 (0.51)
Asymptomatic	5 (2.55)

[Table/Fig-17]: Distribution of clinical symptoms observed in patients with lesions of the lower GI tract. Patients could present with more than one symptom; therefore, percentages do not total 100%.

Patil YV et al., reported non-neoplastic lesions in 83.2% of lower GI endoscopic biopsies, with the colon being the commonest biopsy site (40%). In comparison, the present study showed a higher proportion of non-neoplastic lesions (93.37%), with a marked predominance of appendiceal specimens (83.16%). Similarly, Singh P et al., reported a predominance of non-neoplastic lesions (90.9%) in lower GI endoscopic biopsies, with ulcerative colitis (45.5%) being the most common diagnosis, whereas neoplastic lesions constituted 9.1% of cases. In contrast, the present study showed appendiceal lesions as the predominant component, reflecting differences in specimen type, case selection, and institutional surgical practice [14,15].

In the present study, lower GI tract lesions were most common in the 21-30 years age group 50 (25.5%) cases, followed by the 11-20 years age group 48 (24.5%) cases, with an overall male predominance. Prajapati P et al., reported the highest proportion of lower GI lesions in the 21-30-year age group (22.6%), which is comparable to the present study, where this age group constituted 25.51% of cases [9]. A male predominance was also observed by Prajapati P et al., (61.4%), which closely corresponds to the male predominance in the present study (60.71%; M:F=1.5:1) [9]. Binayke R et al., reported the highest frequency in the 41-50 years group, followed by 31-40 and 21-30 years [13]. Roka K et al., reported the maximum number of patients in the 40-49 years age group, followed by 30-39 years, with a male-to-female ratio of 1.34:1 [10]. Patel VK et al., reported that most neoplastic lesions occurred between 41 and 70 years, with a male-to-female ratio of 1.15:1 [7]. According to Jasani JH et al., lower GIT lesions were more frequent in the 2nd and 3rd decades, with a male-to-female ratio of 1.7:1 [8].

Suvernakar SV also observed male predominance, with a sex ratio of 1.3:1 [11]. Nanavati MG et al., reported maximum cases in the 4th and 5th decades, with a clear male predominance [12]. The relatively younger age distribution in the present study may be partly explained by the high proportion of appendiceal specimens.

Among the 183 non-neoplastic lesions in the present study, appendiceal lesions were most common 161 (87.97%) cases, followed by tubercular lesions of the intestine 8 (4.37%) cases. Patel VK et al., and Jasani JH et al., also reported appendiceal lesions as the most frequent non-neoplastic finding (43.18% and 43.33%, respectively), followed by non-specific inflammation [7,8]. Similarly, Prajapati P et al., reported appendicitis as the predominant non-neoplastic lesion, with acute appendicitis in 148 (31.2%) cases and chronic appendicitis in 78 (49.6%) cases [9]. In their study, the appendix was also the most frequently represented anatomical site, accounting for 248 of 500 cases (49.6%), followed by the small intestine and caecum (21.2%), colon (13.4%), anal canal (8.4%), and rectum (4.2%) [9]. Jasani JH et al., reported 19 cases of tuberculous inflammation characterised by granulomas with central necrosis, peripheral epithelioid cells, lymphocytic infiltration, and multinucleated giant cells [8]. Although caseating granulomas are classically described in tuberculosis, granulomas may occasionally be non caseating, particularly in paucibacillary or early lesions. In the present study, the intestinal tuberculosis cases showing non-caseating granulomas were diagnosed based on the overall histopathological features and clinicopathological correlation. Suvernakar SV reported chronic nonspecific colitis as the predominant lesion (34%) [11]. Nanavati MG et al., reported appendicitis as the most common non-neoplastic lesion (27.4%), followed by non-specific inflammation with perforation, gangrene, and tuberculous inflammation [12].

The predominance of appendiceal lesions in the present study is noteworthy. Of the 196 cases, 163 (83.16%) were appendiceal specimens. This unusually high proportion is likely related to the study setting and the pattern of surgical specimens received during the study period, in which appendicectomy specimens constituted the major proportion of lower GI resection specimens. Consequently, the high representation of appendiceal specimens influenced the overall lesion spectrum, including the predominance of non-neoplastic lesions, the younger age distribution, and the symptom profile. This finding reflects the case mix of the present institution and should not be interpreted as representing the population prevalence of appendiceal disease.

Among the 13 neoplastic lesions in the present study, adenocarcinoma was the most common, followed by tubular adenoma. Regarding the histological grade of adenocarcinoma, the present study showed a predominance of moderately differentiated adenocarcinoma 4/9 (44.44%), followed by well-differentiated 3/9 (33.33%) and poorly differentiated adenocarcinoma 2/9 (22.22%). This pattern is broadly comparable with the study by Patil YV et al., in which moderately differentiated adenocarcinoma was also the predominant subtype among adenocarcinomas. [14] Binayke R et al., reported conventional adenocarcinomas as the majority (70%) of neoplastic lower-GI lesions, with mucinous adenocarcinomas comprising 19% [13]. Roka K et al., observed 6 (20%) cases of adenocarcinoma and 2 (6.66%) cases of adenomatous polyps [10]. Patel VK et al., and Patel MM et al., reported adenocarcinoma as the predominant malignant lesion, accounting for 46.42% and 76.2% of neoplastic lesions, respectively [7,16]. Nanavati MG et al., also found adenocarcinoma to be the most common neoplastic lesion [12]. Jasani JH et al., reported one case of tubular adenoma among 570 cases [8], while Siddiqui B et al., reported four tubular adenomas among 44 lower-GI biopsies [17]. The predominance of adenocarcinoma among neoplastic lesions in the present study is therefore in agreement with previous reports. However, the small number of neoplastic cases limits further comparison of individual tumour types.

In the present study, the appendix was the predominant anatomical site 163 (83.16%) cases, followed by the ileum 17 (8.67%) cases. In contrast, Binayke R et al., reported the rectum as the most frequent site 28 (46.7%) cases, followed by the anal canal 11 (18.5%) cases [13]. Patel VK et al., and Jasani JH et al., also observed the appendix as the most commonly involved site [7,8], whereas Nanavati MG et al., noted that non-neoplastic lesions predominated in the small intestine, while the large intestine harboured most neoplastic lesions [12]. These differences likely reflect variations in study population, specimen type, and institutional surgical practices.

In the present study, abdominal pain was the most common presenting symptom (n=118), followed by vomiting (n=71), fever (n=38), and loss of appetite (n=20). In contrast, Suvernakar SV et al., reported chronic diarrhoea as the predominant symptom (27%), followed by bleeding per rectum (25%), a combination of chronic diarrhoea and bleeding per rectum with abdominal pain (23%), constipation (14%), and cases with additional loss of appetite and weight (11%) [11]. Prabhu Mural MH et al., reported pain abdomen as the most common presenting symptom (86.36%), followed by vomiting (56.81%) [18]. The predominance of abdominal pain and vomiting in the present study may be related to the high proportion of appendiceal lesions.

The present study highlights the predominance of non-neoplastic lesions among lower GI resection specimens, with appendiceal lesions accounting for the majority of cases and adenocarcinoma representing the predominant neoplastic lesion. Histopathological examination remains important for confirming the diagnosis, particularly in resection specimens with clinically suspected inflammatory lesions. The marked predominance of appendiceal specimens should be considered when interpreting and generalising these findings. Future multicentric studies with larger sample sizes and more balanced representation of appendiceal, small-intestinal, and colorectal specimens would provide a broader understanding of the histopathological spectrum of lower GI lesions.

Limitation(s)

The study was conducted at a single tertiary care centre and included only surgically resected specimens; therefore, the findings may not represent the full spectrum of lower GI lesions encountered in the general population or in endoscopic biopsy practice. A major limitation was the marked predominance of appendiceal specimens (163/196; 83.16%), reflecting the institutional surgical case mix, which may have influenced the overall distribution of lesions, age profile, and presenting symptoms. Hence, the findings should not be interpreted as population-based estimates of disease frequency. The relatively small number of neoplastic cases also limited meaningful comparison of individual tumour subtypes. Clinical follow-up and treatment outcomes were not assessed.

CONCLUSION(S)

The present study highlights the predominance of non-neoplastic pathology among surgically resected lower GI specimens, with appendiceal lesions constituting the major proportion. Neoplastic lesions, although less frequent included clinically important malignancies, with adenocarcinoma being the predominant malignant tumour. Overall, the study provides a useful overview of the histopathological spectrum encountered in resected lower GI specimens at a tertiary care centre and contributes region-specific data that may serve as a reference for future clinicopathological and epidemiological studies.

REFERENCES

[1] Standring S, editor. Gray's anatomy: the anatomical basis of clinical practice. 39th ed. Edinburgh: Elsevier Churchill Livingstone; 2005.
[2] National Library of Medicine (US). Lower Gastrointestinal Tract [Internet]. Bethesda (MD): National Library of Medicine; 2026 [cited 2026 Sep 14]. Available from: https://meshb.nlm.nih.gov/record/ui?name=Lower+Gastrointestinal+Tract.

[3] Kumar V, Abbas AK, Aster JC. Robbins and Cotran pathologic basis of disease. 10th ed. Philadelphia: Elsevier; 2021.
[4] Fenoglio-Preiser CM, Noffsinger AE, Stemmerman GN, Lantz PE, Isaacson PG. Gastrointestinal pathology: an atlas and text. 3rd ed. Philadelphia: Lippincott Williams & Wilkins; 2008.
[5] Sulegaon R, Shete S, Kulkarni D. Histopathological spectrum of large intestinal lesions with clinicopathological correlation. J Clin Diagn Res. 2015;9(11):EC30-EC34.
[6] WHO Classification of Tumours Editorial Board. Digestive system tumours. 5th ed. Lyon (France): International Agency for Research on Cancer; 2019.
[7] Patel VK, Goyal AD. Histopathological study of lower gastrointestinal tract lesions. Trop J Pathol Microbiol. 2021;7(4):194-200. Doi: 10.17511/jopm.2021.i04.07.
[8] Jasani JH, Vora SB, Patel NA. Histopathological study of lower gastrointestinal tract biopsies in 600 cases. J Clin Diagn Res. 2021;15(3):EC23-EC26. Doi: 10.7860/JCDR/2021/47391.14756.
[9] Prajapati P, Shah I, Barot H, Goswami H. Histopathological spectrum of lower gastrointestinal tract lesions. Int J Clin Diagn Pathol. 2024;7(3):91-95. Doi: 10.33545/pathol.2024.v7.i3b.588.
[10] Roka K, KC I, Jha SM, Subedi RC, Adhikari A. Pattern of lower gastrointestinal diseases on colonoscopy and histopathological examination in a tertiary care center of Nepal. Med J Shree Birendra Hosp. 2022;21(1):87-92. Doi: 10.3126/mjsbh.v21i1.41983.
[11] Suvernakar SV, More S, Hanmante RD. Histopathological evaluation of lower gastrointestinal tract endoscopic biopsies. Int J Med Sci Diagn Res. 2020;4(11):10-15.
[12] Nanavati MG, Parikh JH, Gamit KS, Modh SD. A histopathological study of intestinal lesions. Int J Sci Res. 2014;3(9):326-30.
[13] Binayke R, Pirosha AA, Govind K, Ramraje S. Histopathological spectrum of lower gastrointestinal tract biopsies: observational study. Scope. 2025;15(2):510-22.
[14] Patil YV, Kesari MV, Kalaivanan V, Bhattacharya I. Histopathological spectrum of endoscopic lower gastrointestinal tract biopsies: a cross-sectional study in a tertiary care hospital in Mumbai, Maharashtra, India. Natl J Lab Med. 2026;15(1):PO01-PO06. Doi: 10.7860/NJLM/2026/84763.2955.
[15] Singh P, Sharma R, Singh T, Kumar N, Gupta M, Bansal M, et al. A study of histopathological spectrum of lower gastrointestinal tract endoscopic biopsies in a tertiary care centre. Int J Multidiscip Res. 2026;8(2):01-08.
[16] Patel MM, Gamit B, Patel PR. Analysis of gastrointestinal malignancy: a 5 years study. Natl J Community Med. 2012;3(3):555-57.
[17] Siddiqui B, Faridi SH, Shehwar D, Ahmed S, Mazumder MA. A study of age-wise spectrum of gastrointestinal biopsies with endoscopic correlation: a 5-year experience from a tertiary health care centre in North India. Int J Pathol Clin Res. 2020;6:113. Doi: 10.23937/2469-5807/1510113.
[18] Prabhu Mural MH, Kalyan NV, Pattanashetti MA, Inamdar SS. Clinico-pathological spectrum of small intestinal lesions at a tertiary care hospital. Al Ameen J Med Sci. 2020;13(4):255-60.

PARTICULARS OF CONTRIBUTORS:
1. Professor, Department of Pathology, PMP Medical College and Hospital, Talcher, Odisha, India.
2. Associate Professor, Department of Pathology, SCB Medical College and Hospital, Cuttack, Odisha, India.
3. Professor, Department of Surgery, PRM Medical College and Hospital, Baripada, Odisha, India.

NAME, ADDRESS, E-MAIL ID OF THE CORRESPONDING AUTHOR:
Dr. Rashmi Rekha Mahapatra,
Associate Professor, Department of Pathology, SCB Medical College and Hospital, Cuttack-753007, Odisha, India.
E-mail: rashmimahapatra123@gmail.com

PLAGIARISM CHECKING METHODS: [Jain H et al.]
- Plagiarism X-checker: Apr 30, 2026
- Manual Googling: Sep 16, 2026
- iThenticate Software: Sep 21, 2026 (9%)

ETYMOLOGY: Author Origin

EMENDATIONS: 8

AUTHOR DECLARATION:
- Financial or Other Competing Interests: None
- Was Ethics Committee Approval obtained for this study? Yes
- Was informed consent obtained from the subjects involved in the study? No
- For any images presented appropriate consent has been obtained from the subjects. NA

Date of Submission: **Apr 01, 2026**
Date of Peer Review: **Jul 31, 2026**
Date of Acceptance: **Sep 22, 2026**
Date of Publishing: **Oct 01, 2026**